

The Effect of the *Polygonum tinctoria* Niram on Atopic Dermatitis in Dinitrochlorobenzene-Induced BALB/c Mice

Han-Na Chu, Jeong-Sang Kim*

Department of Anatomy, College of Oriental Medicine, Dongshin University, Naju 520-714, Korea

In the present study, we investigated the effects of *Polygonum tinctoria* Niram (PTN) on atopic dermatitis (AD) in BALB/c mice induced by 2,4-dinitrochlorobenzene (DNCB). They were divided into four groups; Control, DNCB, DNCB+1%PTN (1% PTN extract) and DNCB+5%PTN (5% PTN extract), for evaluating the change of appearance of skin surface, skin hydration, thickness of epidermis and mast cell numbers during 4 weeks. PTN suppressed symptoms of AD in appearance of skin and increased skin hydration for DNCB+1%PTN and DNCB+5%PTN. Treatment with PTN significantly decreased the levels of eosinophils. In histopathological examination, DNCB+1%PTN and DNCB+5%PTN significantly reduced the thickness of epidermis and number of mast cell in dermis. These results suggested that the PTN improved symptoms of AD in BALB/c mice.

*Correspondence to:
Kim JS,
Tel: +82-61-330-3512
Fax: +82-61-330-3519
E-mail: jskim@dsu.ac.kr

Received June 11, 2014
Revised June 25, 2014
Accepted June 26, 2014

Key Words: *Polygonum tinctoria* Niram, Atopic dermatitis, Mast cell, 2,4-dinitrochlorobenzene, BALB/c mice

INTRODUCTION

Atopic dermatitis (AD) is a chronic inflammatory skin disease that may cause itching as well as inflammation. It has been demonstrated that once allergens get into the system, immunoglobulin E (IgE) from blood B-cells travels to skin mast cells so that they can react with basophile, white blood cell, thereby generating/storing histamines. If there is a repetitive exposure against identical allergens, histamines are discharged to cause allergy symptoms (Choi et al., 2010; Park et al., 2012).

On the other hand, *Polygonum tinctoria* belongs to a Polygonaceae family and is an annual herbaceous plant. The leaves are used as raw indigo and have been known to be effective against fever, detoxification, and oxygen species, making it useful as a therapeutic mean against various inflammations as well as symptoms like cold, jaundice, dysentery, and hematemesis. *P. tinctoria* can be classified into *Polygonum tinctorium* Ait, *Isatis tinctoria*, Sapotaceae family, and *Indigofera tinctoria*; in South Korea, *Polygonum*

tinctorium Ait is the one widely utilized. There are several ways to use *P. tinctoria* as a dye: 1) fermentation of *P. tinctoria* leaves, 2) utilization of fresh *P. tinctoria* leaves, and 3) steaming *P. tinctoria* leaves; of these, the fermentation method is the most conventional one (Lee & Chung, 2012; Jang et al., 2013). There are multiple causes responsible for AD including westernized diets, excessive stress (neuropsychological factors), exposure to endocrine disruptors, decrease in immunity, irregular lifestyle, and genetic propensity. It was estimated that approximately 70%~80% of atopic patients were due to external environments whilst the rest of them were might be because of low immunity according to the present/absence of IgE antibody which is a genetic factor (Haoli et al, 2009). In Unites States, about 20% of population represent atopic disorders whereas it is only shown in 1% in South Korea (Kim et al., 2008); to note, however, 20% of infants, aged between 1~5 years old, are suffering from this atopic disorders and under the treatments for it hence, various medications as well as remedies have been carried out continuously (Kwon, 2013). Consequently, excess medical expenditures as well as

continuous symptoms (e.g., itching and inflammation) are causing refusal of repetitive treatments and stress of patient thereby increasing the number of atopic population. In the present study, we investigated the efficacy of *Polygonum tinctoria* Niram (PTN) extract against the AD like symptoms-induced model so that provide evidence for potential of PTN as drugs, cosmetic products and textile processing.

MATERIALS AND METHODS

Polygonum tinctoria Niram

PTN was obtained from the Naju Natural Dyeing Cultural Center for the study.

Experimental Animals

Six-week-old BALB/c mice were obtained from the Orient Bio (Orient Bio Co., Korea) to utilize as a model of anti-AD. Experimental groups were consisted of negative dinitrochlorobenzene (DNCB) group (Control), positive DNCB group (DNCB), DNCB+1%PTN, and DNCB+5%PTN. The animals were housed in the animal room located at the College of Oriental Medicine of Dongshin University, maintained with consistent conditions (temperature: $21^{\circ}\text{C}\pm 2^{\circ}\text{C}$, humidity: 50%~60%, 12-hour cycle day/night); mice had a free access to commercial pallet chow and water for seven days to acclimate in advance to the experiments.

Induction of Atopic Symptoms in Mice

Hair on the back of BALB/c mice was shaved 24 hours prior to the experiment and then, animals were left for another 24 hours to provide time for healing fine injuries, possibly caused by shaving. Acetone and olive oil was mixed with a ratio of 4:1 and then, 2.5% DNCB (2,4-dinitrochlorobenzene; Sigma-Aldrich Co., USA) and 0.2% DNCB were formulated. The 2.5% DNCB inducer was applied twice with an interval of three days (100 μL per each application) followed by two more application of 0.2% DNCB inducer formulation with an interval of three days (100 μL per each application) to make a total of four times of applications in order to induce atopic symptoms.

Treatment with *Polygonum tinctoria* Niram

In order to alleviate atopic symptoms, PTN was diluted into 1% and 5% concentrations with distilled water. Diluted samples were stored in a refrigerator throughout the study. Mice were applied with PTN over two weeks with an interval of two-days (200 μL per each application) and then symptoms were monitored. To eliminate the possibility that symptoms were naturally cured, 0.2% DNCB was continuously applied for the positive DNCB group (DNCB group) as well as both experimental groups (the DNCB+1%PTN group and the DNCB+5%PTN group) over two weeks (200 μL per each

application).

Macroscopic Observations

Mice were anesthetized using an inhalation anesthetic agent (i.e., isoflurane, 1.5%~3.0% concentration to adult) and then, shaved in advance to take photos of their back.

Measurement of Skin Hydration

The assessment of skin hydration was performed using a corneometer CM825 (Courage-Khazaka Electronic GmbH, Germany). This corneometer measures a degree of skin hydration (e.g., stratum corneum) via the capacitance method. It is able to measure hydration levels of underneath stratum corneum up to 10~20 μm using the conductor track in electric scatter field hence, widely used as an assessment index. The higher degree of hydration measured the higher signal in the instrument obtained. The unit for the measurement is the arbitrary unit (AU) (Choi, 2006).

Blood Analysis

Urethane (75 mg/kg) was administrated via intraperitoneal injection and then the chest was opened to draw blood from the heart. Collected blood samples were transferred into ethilen dianmin acetic acid test tubes and eosinophil was measured immediately using a haemacytometer (Hemavet 950 FS; Drew-Scientific, USA).

Measurement of Spleen Index

Spleens were collected and then weighted. The spleen index was defined as the weight of spleen (mg) divided by the body weight (g) at the end of the experiment.

Histological Analysis

Once sacrificed, back skin tissues, one centimeter in width and length, were harvested and fixed with 10% formalin over 24 hours. With a gradient concentration of ethanol, tissues were dehydrated by immersing into 30%, 50%, 70%, 80%, 90%, 95%, 100% (I), and 100% (II), consecutively and then, clearing processes were done with xylene. Tissues were embedded in paraffin and sliced to make 5 μm thick sections using a microtome. Sliced sections were attached on a slide glass and deparaffinized with xylene followed by hydration process with a downward gradient of ethanol (i.e., 100%, 90%, and 80% ethanol) for five minutes per each concentration. Resulting sections were stained via hematoxylin & eosin staining to differentiate from epidermis, dermis, keratinocytes, neutrophils, eosinophil, other cells, and edema and then, dehydrated. Sections were sealed with Canada balsam and monitored using an optical microscopy (Nikon Eclipse 80i; Nikon, Japan) equipped with a digital camera at $\times 200$ magnification; the epidermis thickness was measured from five sections per each mouse.

Toluidine Blue Staining

Mast cells were stained in order to monitor infiltration of inflammation cells in skin tissues. Tissue sections were stained with a mixture of 1% toluidine blue stock solution in 70% alcohol and 1% sodium chloride (pH 2.3). Tissue sections were deparaffinized with xylene and then, hydrated subsequently with 100%, 90%, and 80% ethanol for five minutes per each concentration. Then, samples were stained in toluidine blue working solution for 2~3 minutes. Stained sections were washed with distilled water for three times and quickly immersed in 50%, 70%, 80%, 90%, 95%, 100% (I), and 100% (II) ethanol. Upon eliminate water in tissues sections, clearing processes were performed twice using xylene for three minutes per each. Sections were sealed with Canada balsam and then monitored using an optical microscopy at $\times 200$ magnification; mast cells were counted from five sections per each mouse.

Statistical Analysis

In the study, results were expressed as mean \pm standard error. Statistical differences between the DNCB group and experimental groups were analyzed using Student's t-test by Microsoft Excel (Microsoft, USA). A p-value less than 0.05 was considered statistically significant.

RESULTS

Macroscopic Observations

Atopic symptoms were induced with DNCB formulation and then, mice dorsal skins were monitored while treating with PTN (Fig. 1). In the negative DNCB (Control), any noticeable change was observed whereas atopic symptoms in the DNCB group were not alleviated throughout the study. Once symptoms were induced, there are eschar formed which make mice scratching to eliminate them due to itch. Consequently, we were able to confirm that atopic symptoms were successfully induced through the observations of erythema, bleeding, skin dryness, inflammation, lichenification, scaling, spots, and hair loss. Upon induction, PTN was applied on dorsal skins over two weeks with two-days of interval. Application of PTN noticeably alleviated severe AD in mice; skin surface were becoming smoother and many red-colored wounds were removed. Through these macroscopic observations, it was clearly confirmed that DNCB induced atopic symptoms were alleviated by application of PTN. In addition, in the DNCB+5%PTN group, such protective effects were more pronounced when compared to DNCB+1%PTN, suggesting a dose-dependent efficacy of PTN against atopic symptoms.

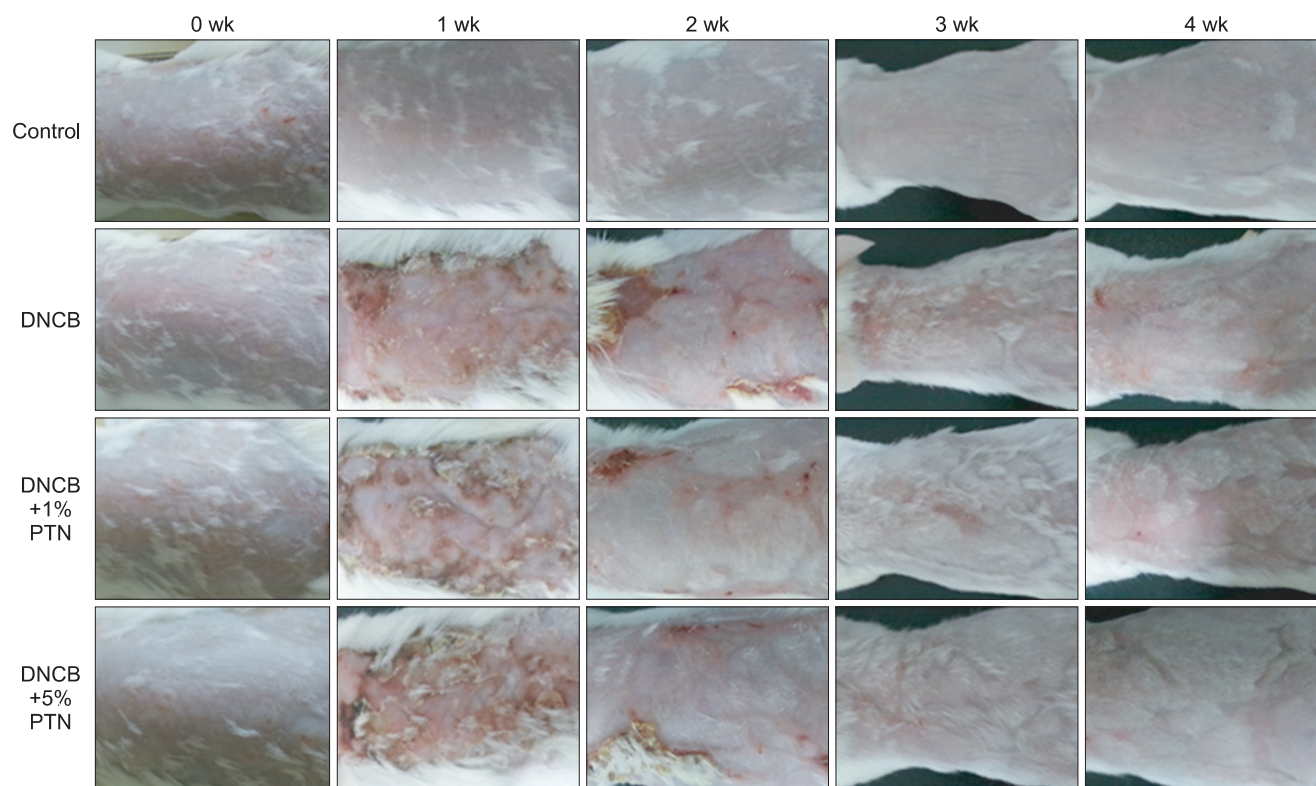


Fig. 1. Effect of *Polygonum tinctoria* Niram (PTN) on clinical skin features of dinitrochlorobenzene (DNCB)-applied BALB/c mice. Control, no treated group; DNCB, DNCB only group; DNCB+1%PTN, 1% PTN extract group; DNCB+5%PTN, 5% PTN extract group.

Measurement of the Moisture Content

The skin hydration of dorsal skin of BALB/c mice was measured using the corneometer throughout the study (Fig. 2). All groups represented the similar degree of skin hydration in the beginning of the study, but it was drastically decreased upon the induction of atopic symptoms by DNCB in both positive DNCB group (DNCB) and experimental groups (DNCB+1%PTN and DNCB+5%PTN). No effect was found in the negative DNCB group (Control; 24.3 ± 3.4 AU) while the positive and experimental groups showed significantly lowered skin hydration. Once applied with PTN, experimental group mice started to increase the level of skin hydration from the 25th days of experiment. On day 30,

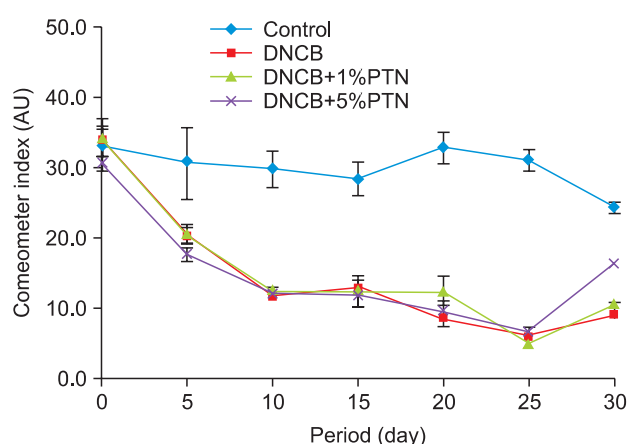


Fig. 2. Changes of the mean value of the skin hydration in dosal skin of dinitrochlorobenzene (DNCB)-applied BALB/c mice. Control, no treated group; DNCB, DNCB only group; DNCB+1%PTN, 1% PTN extract group; DNCB+5%PTN, 5% PTN extract group; AU, arbitrary unit.

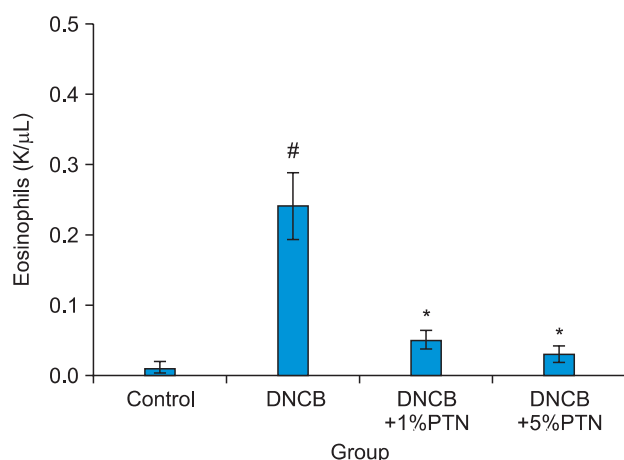


Fig. 3. Number of blood eosinophil in dinitrochlorobenzene (DNCB)-applied BALB/c mice. All values are mean±standard error (n=5). Control, no treated group; DNCB, DNCB only group; DNCB+1%PTN, 1% PTN extract group; DNCB+5%PTN, 5% PTN extract group. Significant differences were compared with Control at #p<0.05 or DNCB at *p<0.05.

although there was no significant effect was noted between the positive DNCB group (DNCB) versus DNCB+1%PTN group, the DNCB+5%PTN group exhibited the increase in skin hydration (16.4 ± 3.3 AU). As results, we were able to demonstrate that PTN application influenced the degree of skin hydration and such effects were more pronounced as the concentration of PTN was elevated.

Measurement of Eosinophil

In the present study, we found the significant increase in the level of eosinophil in the positive DNCB group (DNCB) mice compared to those of negative DNCB (Control) (0.01 ± 0.01 K/μL versus 0.24 ± 0.05 K/μL for Control and DNCB group, respectively) as well as experimental groups. In the both experimental groups, the levels of eosinophil were significantly lowered compared to the positive DNCB group (0.05 ± 0.01 K/μL and 0.03 ± 0.01 K/μL for the DNCB+1%PTN group and DNCB+5%PTN group, respectively; Fig. 3).

Measurement of Spleen Index

In order to investigate immune responses of mice against DNCB, we sacrificed animals and harvested spleen to measure weights of spleens. Compared to the negative DNCB group (Control), mice of the positive DNCB (DNCB) represented heavier spleen weights (3.65 ± 0.46 mg/g). On the other hand, both experimental group mice had lighter spleen weights but differences were not statistically significant (3.44 ± 0.29 mg/g and 3.57 ± 0.20 mg/g for the DNCB+1%PTN group and DNCB+5%PTN group, respectively; Fig. 4).

Histological Observations

Skin tissues were stained using H&E in order to monitor changes in dorsal skin surface of BALB/c mice. In the negative

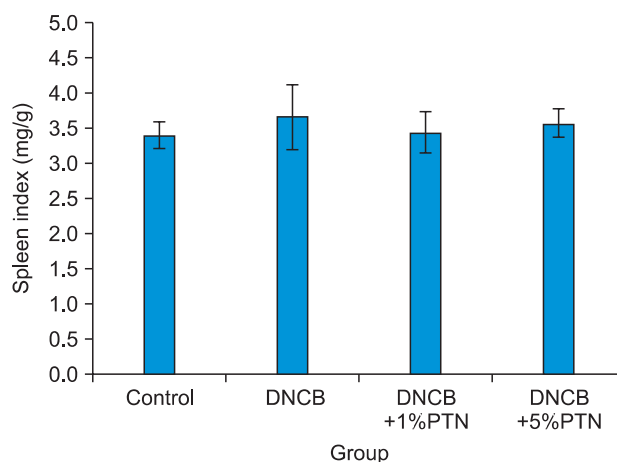


Fig. 4. Spleen weight in dinitrochlorobenzene (DNCB)-applied BALB/c mice. Values are spleen weight/body weight. Control, no treated group; DNCB, DNCB only group; DNCB+1%PTN, 1% PTN extract group; DNCB+5%PTN, 5% PTN extract group.

DNCB group (Control), epidermis was thin and represented uniform connective tissues (Fig. 5A). Upon the applications of DNCB, in the positive DNCB group (DNCB), the epidermis thickness was expanded accompanying with thick dislocation of stratum corneum (Fig. 5B). On the other hand, in both experimental groups (Fig. 5C and D for the DNCB+1%PTN group and the DNCB+5%PTN group, respectively) the epidermis thickness was much thinner than the positive DNCB group (DNCB) and the degree of dislocation of stratum corneum was significantly improved.

Thickness of Epidermis

Dorsal skin tissues of BALB/c mice were stained with H&E and then the thickness of epidermis was measured using the microscope, capable to calibrate. As shown in the Fig. 6, the thickness of epidermis was the thinnest in the negative DNCB group ($57.00 \pm 5.97 \mu\text{m}$; Control) in contrast it was found to be the thickest in the positive DNCB group ($210.00 \pm 6.15 \mu\text{m}$; DNCB). In the experimental groups, both groups exhibited the significantly decreased thickness of epidermis compared to that of the positive DNCB group ($70.00 \pm 5.58 \mu\text{m}$ and $71.00 \pm 3.48 \mu\text{m}$ for the DNCB+1%PTN group and

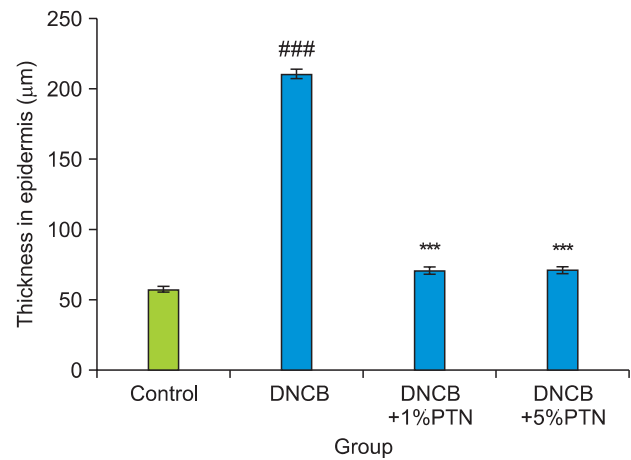


Fig. 6. Thickness of epidermis in dosal skin of dinitrochlorobenzene (DNCB)-applied BALB/c mice. All values are mean±standard error (n=5). Control, no treated group; DNCB, DNCB only group; DNCB+1%PTN, 1% PTN extract group; DNCB+5%PTN, 5% PTN extract group. Significant differences were compared with Control at ###p<0.001; ***p<0.001.

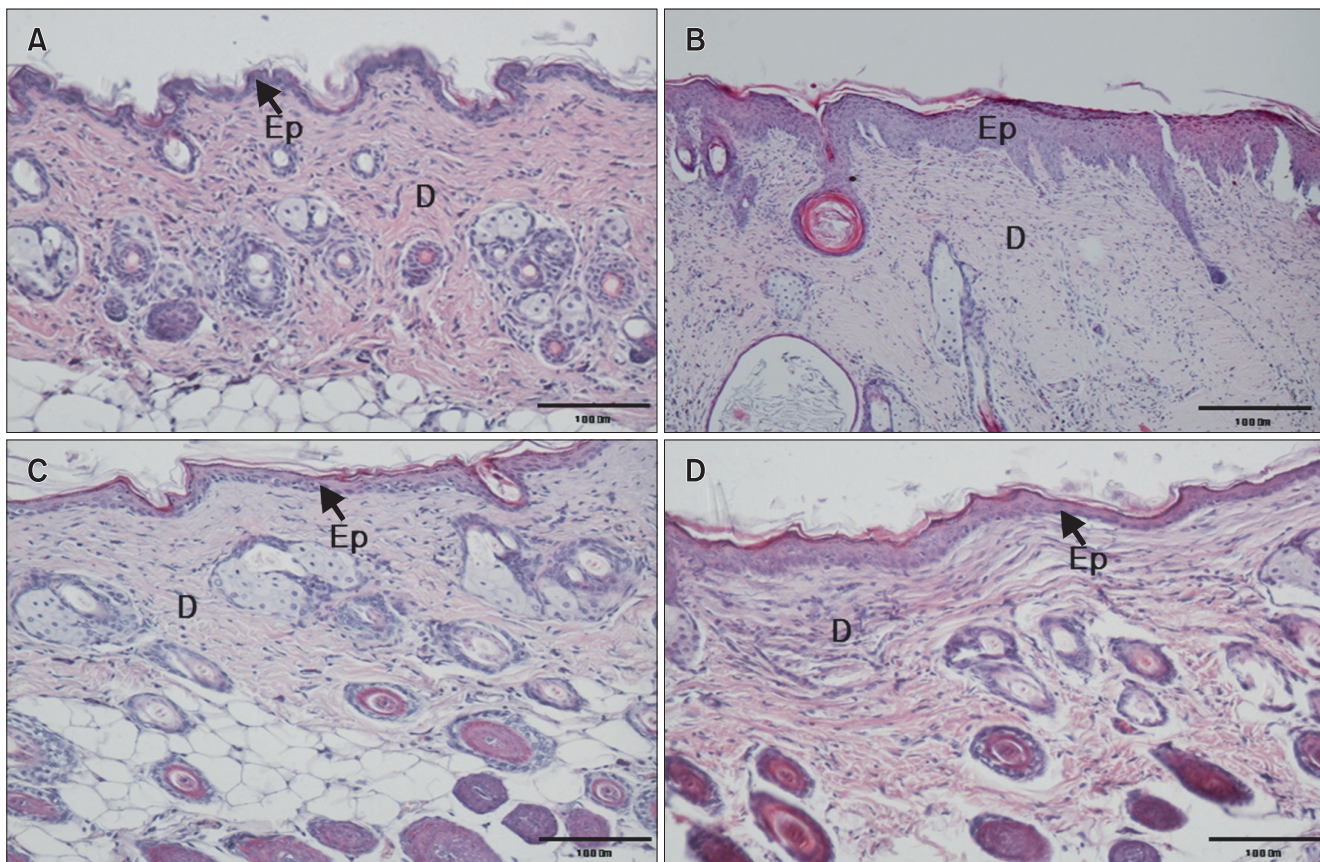


Fig. 5. Histology of dosal skin lesions in dinitrochlorobenzene (DNCB)-applied BALB/c mice (H&E stain, ×200). (A) Control, no treated group. (B) DNCB, DNCB only group. (C) DNCB+1%PTN, 1% PTN extract group. (D) DNCB+5%PTN, 5% PTN extract group. Ep, epidermis; D, dermis.

the DNCB+5%PTN group, respectively; Fig. 6). Thus, it is suggested that applications of PTN on the dorsal skin may positively contribute on AD treatment given the mitigated symptoms of dermatitis in BALB/c mice.

Toluidine Blue Staining

Mast cells of dermis in AD-mice were observed via staining with toluidine blue. In the negative DNCB group, almost no mast cells were observed (Fig. 7A) in contrast, multiple mast cells are present in the positive DNCB group (Fig. 7B), indicating that application of DNCB successfully induced AD like symptoms. In the experimental groups, mast cells were significantly decreased compared to the positive DNCB group (Fig. 7C and D).

Mast Cell Counting

BALB/c mice dorsal dermis was stained via toluidine blue staining and then mast cell numbers were counted. In the Control group, the number of mast cells was lowest

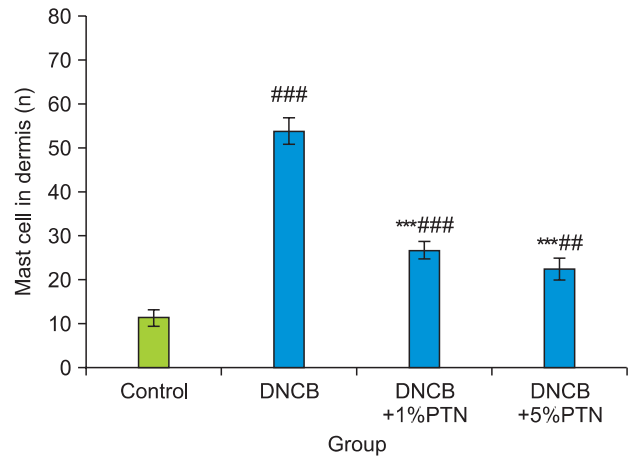


Fig. 8. Number of mast cells in dermis of dinitrochlorobenzene (DNCB)-applied BALB/c mice. All values are mean±standard error (n=5). Control, no treated group; DNCB, DNCB only group; DNCB+1%PTN, 1% PTN extract group; DNCB+5%PTN, 5% PTN extract group. Significant differences were compared with Control at ##p<0.01; ###p<0.001; ***p<0.001.

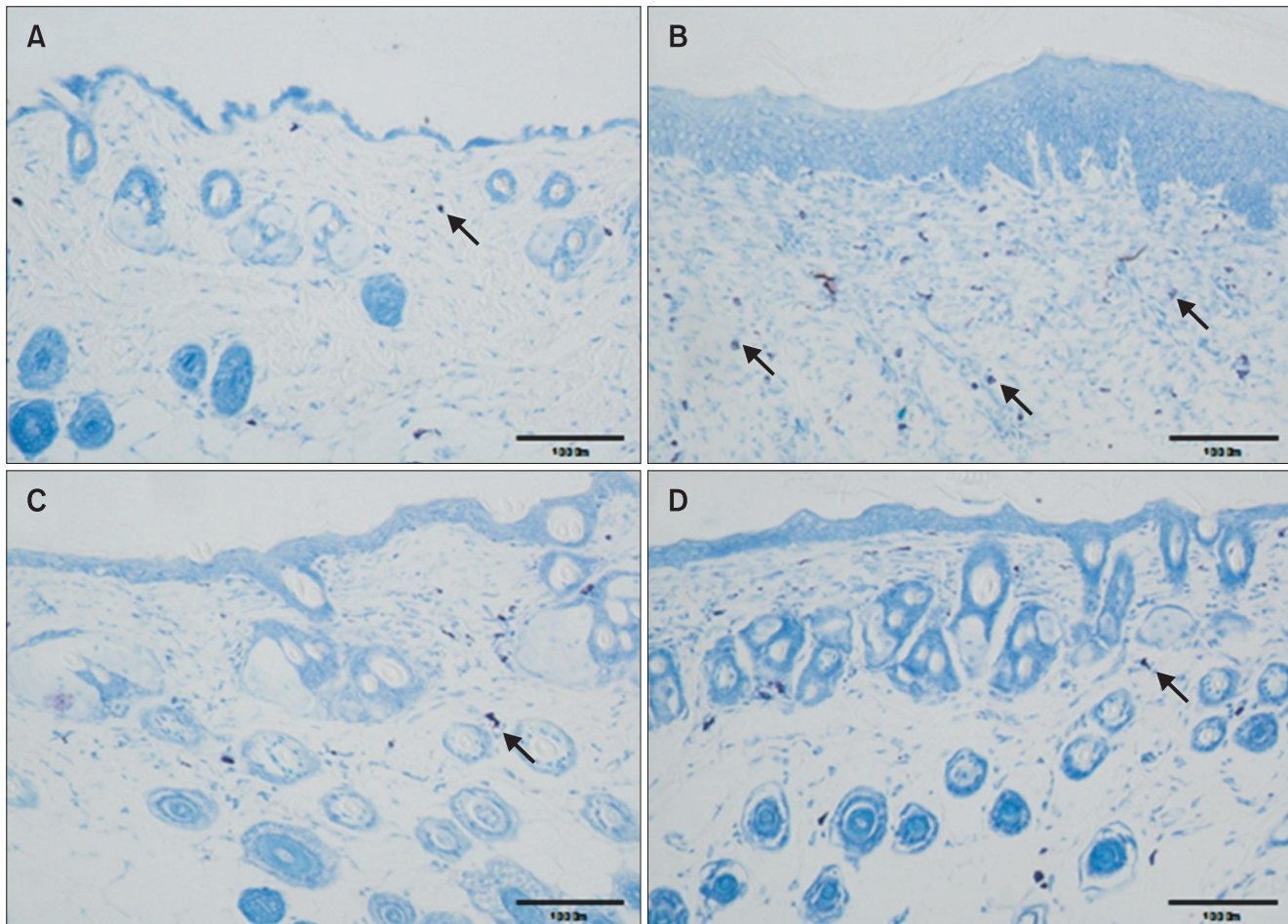


Fig. 7. Effect of *Polygonum tinctoria* Niram on mast cell infiltration in dosal skin of dinitrochlorobenzene (DNCB)-applied BALB/c mice (Toluidine blue stain, ×200). (A) Control, no treated group. (B) DNCB, DNCB only group. (C) DNCB+1%PTN, 1% PTN extract group. (D) DNCB+5%PTN, 5% PTN extract group. Arrows indicate mast cells.

(11.20 ± 1.90 cell/ 0.1 mm^2) while it was shown to be the highest in the positive DNCB group (53.70 ± 3.07 cell/ 0.1 mm^2). In the both experiment groups (i.e., DNCB+1%PTN and DNCB+5%PTN group), the numbers of mast cells were significantly decreased compared to that of DNCB group (DNCB) (26.60 ± 2.00 cell/ 0.1 mm^2 and 22.30 ± 2.42 cell/ 0.1 mm^2 , respectively; Fig. 8).

DISCUSSION

In this study, PTN significantly improved the AD-like symptoms of BALB/c mice. The levels of eosinophil were significantly lowered in the both experimental groups. It has been widely accepted that the level of eosinophil in peripheral blood and tissues is elevated upon allergic diseases as well as parasitic infections. AD is a type of hyper sensitive immune reactions occurring in both blood and skins due to cellular activations that are contributed by the differentiation of T cells to Th2 cells. In this series of actions, Th2 cells produce interleukin (IL)-4, IL-5, IL-9, and IL-13 thereby increasing IgE levels in B cell which result the degranulation of mast cells as well as activation of eosinophil (Yagi et al., 2002; Jencrowicz et al., 2007; Park & Kim, 2008).

Skin tissue of mice treated PTN were reduced in thickness of epidermis. These results are in good agreement with other previous investigations reporting that even though there may not be any histopathological change observed in advance to diseases, symptoms such as cell infiltration, proliferation of papilloma, and increase in the thickness of the epidermis are often appeared following the diseases' initiation. In addition, other abnormal symptoms including epithelial defect, eschar, and parakeratosis are frequently observed in some cases (Mizutani et al., 2004; Park et al., 2012; Kwon, 2013). Taken together, we clearly demonstrated that PTN applications influenced the DNCB of epidermal cell proliferation.

It has been reported that increase in thickness of epidermis is caused by hyperkeratosis accompanying abnormal keratosis as well as hyperplastic cells (Zhou et al., 2014). In other previous reports, herb extracts (Lee et al., 2008), magnesium rich ocean mineral water (Kim et al., 2008), ginsengs (Kim et al., 2010), chamomile oil (Lee et al., 2011), Hwangnyeonhaedok-tang (Ki et al., 2013) were also effective to decrease the epidermis

thickness as shown in the present study.

Mast cells are produced from hematopoietic stem cells and travel to tissues via blood stream; depending upon the cytokine levels and types, these cells can be proliferated and modified (Shukla et al., 2005; Choi et al, 2012). The mast cells can induce chronic inflammation reactions via secreting allergic mediators and inflammatory cytokines and cause itch in allergy; these cells have been considered as an important factor to explain mechanisms responsible for various immune deficiencies and disorders (Facoetti et al., 2006; Seema & Pattankar, 2011). In order to monitor mast cells, the toluidine blue staining method is performed. This staining allows observing both rodent and human connective tissues; purple colored, metachromatic staining reactive cells are observed and evaluated (Lee et al., 2006).

It was previously demonstrated that decreased in numbers of mast cells might be due to efficacy of therapeutic agents (Ahn et al., 2009; Nagai & Okunishi, 2009; Li et al., 2010; Zheng et al., 2011; Li et al., 2013). As we demonstrated, PTC significantly lowered the numbers of mast cells in mice dorsal skin, suggesting its suppressing potential against AD like symptoms and providing a possibility to utilize PTN as a raw material for the development of therapeutic agents.

CONCLUSIONS

We investigated the effects of PTN on AD in BALB/c mice. PTN is to suppress the symptoms of AD and increased moisture content in DNCB+5%PTN group. The ratio of eosinophil from blood significantly decreased in the experimental groups compared with DNCB group. The results of histopathological observation, the thickness of epidermis significantly decreased in the experimental groups compared with DNCB group. The number of mast cells from dermis significantly decreased in the experimental group. These results suggested that PTN improved the AD's symptoms in BALB/c mice.

CONFLICT OF INTEREST

No potential conflict of interest relevant to this article was reported.

REFERENCES

- Ahn J Y, Im L R, Kim J H, Park J H, Kim D K, and Lee Y M (2009) Effects of Rumecis Radix water extract on development of atopic dermatitis in BALB/c mice. *Korean J. Pharmacogn.* **40**, 218-223.
- Choi M J, Jung H K, Jeong Y S, Park S C, and Hong J H (2010) Anti-allergic activities of fermented *Eriobotrya japonica* and *Saurus chinensis* extracts in 2,4-dinitrochlorobenzene-induced BALB/c mice. *J. Korean Soc. Food Sci. Nutr.* **39**, 1611-1618.
- Choi E Y (2006) Comparison of state of skin surface using skin instrumental measurements. *Korean J. Aesthet. Cosmetol.* **4**, 1-10.
- Choi Y J, Lee C S, and Kim J M (2012) Distribution of mouse uterine mast cells during estrous cycles. *Dev. Reprod.* **16**, 113-120.

- Facoetti A, Fakkarini S, Miserere S, Bertolotti A, Ferrero I, Tozzi R, Gatti C, Palladimi G, Perlini S, and Nano R (2006) Histochemical study of cardiac mast cells degranulation and collagen deposition: interaction with the catecholaminergic system in the rat. *European J. Histochem.* **50**, 133-140.
- Haoli J, Rui H, Michiko O, and Raif S G (2009) Animal models of atopic dermatitis. *J. Invest. Dermatol.* **129**, 31-40.
- Jang S E, Lee N K, Lee Y R, Choi M S, and Jeong Y S (2013) Isolation and characterization of *Commanomase* sp. and *Microbacterium* sp. from deep blue sediment dye of *Polygonum tictoria*, Niram. *J. Korean Soc. Biotechnol. Bioeng.* **28**, 60-64.
- Jencrowicz D, Czarnecka-Operacz M, and Silny W (2007) Peripheral blood eosinophilia in atopic dermatitis. *Acta Dermatov. APA* **16**, 47-52.
- Ki H P, Jang S I, and You Y G (2013) Ameliorative effects of Hwangnyeonhaedok-tang on atopic dermatitis. *Herb. Form. Sci.* **21**, 80-90.
- Kim D H, Lee K J, Qi X F, Lee Y M, Yoon Y S, Kim J L, Chang B S, and Ryang Y S (2008) The effects of magnesium rich sea mineral water on atopic dermatitis-like skin lesions in hairless mice. *Korean J. Microsc.* **38**, 167-174.
- Kim H S, Oh T H, Song J C, Kim D I, Lim A K, Yang D C, In J G, Kim Y C, and Kim K S (2010) Inhibitory effects of korean red ginseng extract on atopic dermatitis in NC/Nga mice. *Lab. Anim. Res.* **26**, 365-271.
- Kwon H Y (2013) The anti-atopic effect on flavonol content from *Ginkgo biloba* leaves on NC/Nga murine model with mast cell and DNCB-induced atopy. Dept. of Beauty and Health Care. Thesis, (Graduate School of Daejeon University, Daejeon).
- Lee G S, Pena I D, Choi J Y, Yoon S Y, and Choi J H (2008) Effect of SPZZC, a composition of herb extracts, on atopic dermatitis in BALB/c and NC/Nga mouse. *J. Pharm. Soc. Korea* **52**, 232-239.
- Lee M S and Chung K H (2012) The development bedclothes design through the application of natural indigo dyeing. *J. Korean Soc. Design Culture* **18**, 356-367.
- Lee S H, Kim Y C, and Lee J S (2011) A study on potential effectiveness of german chamomile oil in Atopic dermatitis. *J. Korea Soc. Beauty Art* **12**, 37-48.
- Lee Y H, Kim K T, Han U H, Kim H T, Park B G, Lee M S, and Song C H (2006) Histochemical Characteristics and Ultrastructure of Mast Cells in Pheasant (*Phasianus colchicus*). *Korean J. Anat.* **39**, 367-374.
- Li C, Lasse S, Lee P, Nakasaki M, Chen S W, Yamasaki K, Gallo R L, and Jamora C (2010) Development of atopic dermatitis-like skin disease from the chronic loss of epidermal caspase-8. *Proceedings of the National Academy of Sciences of the United States of America* **107**, 22248-22254.
- Li Y Z, Lu X Y, Jiang W, and Li L F (2013) Anti-inflammatory effect of Qingpeng ointment in atopic dermatitis-like murine model. *Evid. Based Complement. Alternat. Med.* doi: 10.1155/2013/907016.
- Mizutani H, Nishiguchi T, and Murakami T (2004) Animal models of atopic dermatitis. *J. Japan Med. Assoc.* **47**, 501-507.
- Nagai M and Okunishi I (2009) The effect of Wasabi Rhizome extract on atopic dermatitis-like symptoms in HR-1 hairless mice. *J. Nutr. Sci. Vitaminol.* **55**, 195-200.
- Park B S, Park S O, Ahn Y S, Ryu C M, Noh H Y, and Noh G Y (2012) Therapeutic effects of atobeauty cream in atopic dermatitis model mice induced DN CB. *Research J. Med. Sci.* **6**, 71-76.
- Park D H and Kim Y U (2008) Screening of anti-atopic dermatitis material by using NC/Nga mouse whole blood system. *Immun. Netw.* **8**, 98-105.
- Park S O, Park B S, Ryu C M, and Ahn Y S (2012) Effect of herb extracts mixed with *Houttuynia Cordata* on antiatopic dermatitis in DNCB-included BALB/c mouse. *J. Korean Oil Chem. Soc.* **29**, 175-183.
- Seema V and Pattankar V L (2011) Mast cell variation in some commonly encountered lesions of salivary glands. *Res. J. Pharm. Biol. Chem. Sci.* **2**, 19-27.
- Shukla S A, Veerappan R, Whittimore J S, Miller L E, and Youngberg G A (2005) Mast cell ultrastructure and staining in tissue. *Method Mol. Biol.* **315**, 63-76.
- Yagi R, Nagai H, Iigo Y, Akimoto T, Arai T, and Kubo M (2002) Development of atopic dermatitis-like skin lesions in STAT6-deficient NC/Nga mice. *J. Immunol.* **168**, 2020-2027.
- Zheng H, Jeong Y J, Song J M, and Ji G E (2011) Oral administration of ginsenoside Rh1 inhibits the development of atopic dermatitis-like skin lesions induced by oxazolone in hairless mice. *Int. Immunopharm.* **11**, 511-518.
- Zhou S L, Tan G H, Huang F Y, Wang H, Lin Y Y, and Chen S L (2014) Sanpao herbs inhibit development of atopic dermatitis in Balb/c mice. *Asian Pac. J. Allergy Immunol.* **32**, 3-7.